

李沛威

ALEX LEE



05

CARDIOVASCULAR MEDICINE

Heart Diseases - Cardiac Imaging and Intervention

Principal Investigator



Alex Lee

Team members



Randolph Wong, Yiting Fan, Kevin Kam, Kent So, Xueting Wang, Kandy Li, Sophia Yip, Judy Yiu, Ada Yu, Josie Chow, Margaret Lee

Research Progress Summary

The team led by Alex Lee has published a study on adult onset cardiac variant Fabry disease, for the first time in Hong Kong. They identified a high prevalence of undiagnosed Fabry disease among Chinese patients with left ventricular hypertrophy. In the area of structural and valvular heart disease, they published a research article on novel mechanism of functional mitral regurgitation in JACC Asia; they developed a new automated software for 3D analysis of the left atrial appendage for device closure in collaboration with School of Technology, IPCA, Barcelos, Portugal and published their result in the *Journal of American Society of Echocardiography*. Using artificial intelligence, they developed in collaboration with the School of Biomedical Engineering, Sun Yat-sen University, Guangzhou, People's Republic of China, a deep learning-based automated left ventricular ejection fraction assessment using 2-D echocardiography, and published their results in *American Journal of Physiology*. Additionally, they published an original article on *The Annals of Thoracic Surgery* on the prevalence of thoracic aortic aneurysm in

hypertensive patients detected using point-of-care ultrasound device.

The team has successfully organised the "Echo guidance for screening and interventions in Structural Heart Diseases" online training in March, May and October 2021, with excellent feedback from the 49 attendees from Asia-pacific region. "Echocardiography in Heart Failure: Beyond Diagnosis Live Webinar" was held in November 2021 and attracted over 360 international attendees from around the globe.

"CUHK POCUS for Heart Failure Introductory Preceptorship Program" was held in April to September 2021 for 29 doctors in Hong Kong to provide training on POCUS image acquisition and interpretation and the use of POCUS in clinical decisions for management of heart failure. The team also held "CUHK Transthoracic Echo Course for Anesthesiologists" to develop trainer competence in comprehensive echocardiographic examination for 24 Hong Kong doctors.

Research and Scholarship

Research Awards and Recognitions

Member's Name	Details	
	Award	Organisation
Alex Lee	Expertise in Three-Dimensional Echocardiography	Expertscape

Academic Editorship

Member's Name	Details	
	Role	Journal
Alex Lee	JAPSC Editorial Board Member	Journal of Asian Pacific Society of Cardiology
	Section Editor	JACC: Asia
	Associate Editor	Frontiers in Cardiovascular Medicine


Reviewer of Journal / Conference

Member's Name	Details	
	Role	Journal / Conference
Alex Lee	Reviewer	JASE
		Circulation Cardiovascular Imaging
		JACC: Asia
	Abstract grader	EuroEcho 2021 Congress

Grants and Consultancy

Name	Project Title	Funding Source	Start Date (dd/mm/yyyy)	End Date (dd/mm/yyyy)	Amount (HK\$)
Alex Lee	3D Echo Biobank for Atrioventricular Valve Regurgitation and Transcatheter Repair	Abbott Medical (Hong Kong) Ltd	01/09/2021	31/08/2023	900,000

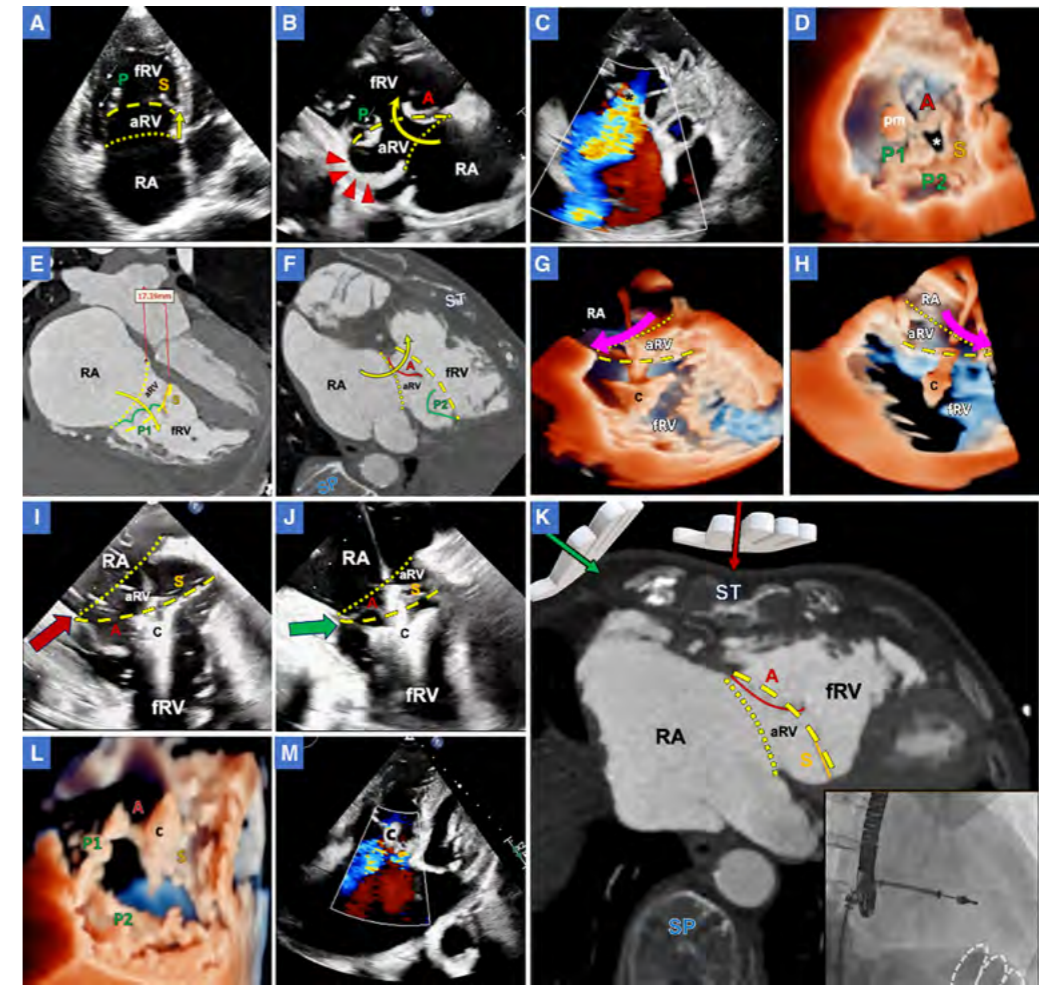
Name	Project Title	Funding Source	Start Date (dd/mm/yyyy)	End Date (dd/mm/yyyy)	Amount (HK\$)
Alex Lee	3D Printing Technology for Planning Left Atrial Appendage Occlusion: A Randomised Trial	Food and Health Bureau – Health and Medical Research Fund	01/05/2018	30/04/2021	1,191,977
	A Multinational, Multicenter Study to Assess the Effects of Oral Sildenafil on Mortality in Adults with Pulmonary Arterial Hypertension	Pfizer Corporation Hong Kong Limited	25/10/2018	31/08/2023	2,399,028
	Speeding up Examination of Heart Diseases through the Use of 3D Echocardiography and Machine Learning	Innovation & Technology Commission – Midstream Research Programme for Universities	01/04/2021	31/03/2023	1,251,200
	Automatic Retinal Image Analysis (ARIA) to Predict Coronary Artery Disease in HIV-infected Individuals	Centre for Health Protection AIDS Trust Fund	04/2019	03/2021	560,462
	Non-interventional Study on Edoxaban Treatment in Routine Clinical Practice for Patients with Non Valvular Atrial Fibrillation (ETNA-AF-Hong Kong)	Daiichi Sankyo Hong Kong Ltd	29/09/2017	30/09/2021	176,772.5



Publications

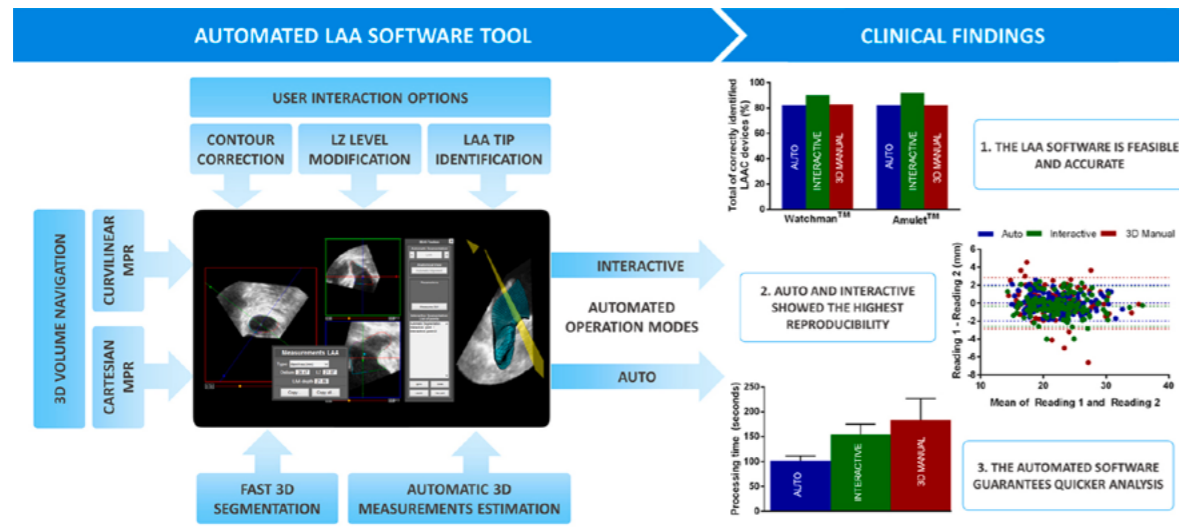
A. Journal Papers

1. Fan Y, Kam K, So K, Lam YY, Lee APW. Imaging for transcatheter edge-to-edge repair for tricuspid regurgitation in ebstein anomaly. *Circulation: Cardiovascular Imaging*. 2021;14(11):e013327. doi:10.1161/circimaging.121.013327. (Editorial, Epub ahead of print)
2. Chan JSK, Lau DHH, Fan Y, Lee APW. Age-related changes in left ventricular vortex formation and flow energetics. *Journal of Clinical Medicine*. 2021;10(16):3619. doi:10.3390/jcm10163619.
3. Lee APW, Fan Y, Baig FN, Lam YY. Mechanisms of mitral regurgitation: New insights from 3D echocardiography and implications for transcatheter repair. *JACC: Asia*. 2021;1(1):115-6. doi:10.1016/j.jacasi.2021.04.004. (Letter)
4. Mao Z, Zhao L, Huang S, Fan Y, Lee APW. Direct 3D ultrasound fusion for transesophageal echocardiography. *Computers in Biology and Medicine*. 2021;134:104502. doi:10.1016/j.compbiomed.2021.104502.
5. Fan Y, Lee APW. Valvular disease and heart failure with preserved ejection fraction. *Heart Failure Clinics*. 2021;17(3):387-395. doi:10.1016/j.hfc.2021.02.005.
6. Fan Y, Chan TN, Chow JTY, Kam KKH, Chi WK, Chan JYS, Fung E, Tong MMP, Wong JKT, Choi PCL, Chan DKH, Sheng B, Lee APW. High prevalence of late-onset fabry cardiomyopathy in a cohort of 499 non-selective patients with left ventricular hypertrophy: The Asian fabry cardiomyopathy high-risk screening study (Asian-fame). *Journal of Clinical Medicine*. 2021;10(10):2160. doi:10.3390/jcm10102160.
7. Zhong X, Chen W, Shi Z, Huan Z, Ma L, Liu W, Yang X, Xu Y, Jiang Y, Lee APW, Guo R. Three-dimensional transesophageal echocardiography measurement of mitral valve area in patients with rheumatic mitral stenosis: Multiplanar reconstruction or 3D direct planimetry? *International Journal of Cardiovascular Imaging*. 2021;37(1):99-107. doi:10.1007/s10554-020-01950-1.



Transcatheter edge-to-edge repair (TEER) for tricuspid valve regurgitation in Ebstein anomaly
 Preprocedural echocardiography (A–D) and computed tomography (CT; E and F). **A**, Four-chamber view showing apical displacement (yellow arrow) of the septal (S) and posterior leaflet (P) with leaflet tethering (white arrows) to underlying right ventricle (RV) myocardium. **B**, RV inflow view showing spiral displacement (curved arrow) of the functional tricuspid valve (TV) orifice and delamination/thinning of the RV inlet myocardium (red arrow heads). **C**, Wide leaflet gap with torrential tricuspid regurgitation (TR). **D**, Three-dimensional (3D) echocardiography showing 4-leaflet morphology (type IIIB) of the TV without leaflet fenestrations. **E** and **F**, CT showing anterior and superior rotation of the functional tricuspid orifice. **G** through **J**, Intra-procedural imaging. Live 3D transesophageal echocardiography (TEE) in the low esophageal TV-focused (**G**) and RV inflow-outflow views (**H**) showing, respectively, outward rotation of the guide and superior steering of the clip delivery system (CDS; pink arrows) to align with the rotated TV plane. **I**, Failed initial attempts to grasp both leaflets with anterior leaflet losing capture. Sternal compression (red arrow) did not reduce TV dimension. **J**, Right parasternal chest compression (green arrow) facilitated leaflet grasping. **K**, Relations between compressive directions and TV plane orientation on CT. Oblique right parasternal compression (palm with green arrow) would markedly reduce functional tricuspid orifice dimension (dashed line). Small insert: operator’s hand position (dashed outline) on right anterior oblique fluoroscopic view during right parasternal compression. **L**, Postprocedural 3D echocardiography showing one clip implanted in the anteroseptal commissure with TV bicuspidization. **M**, TR reduction with mild-to-moderate residual regurgitation at 4 mo. A indicates anterior leaflet; aRV, atrialized RV; asterisk, leaflet coaptation gap; C, MitraClip; dashed line, functional tricuspid orifice; dotted line, anatomic atrioventricular groove; fRV, functional RV; pm, anterior papillary muscle; RA, right atrium; SP, spine; and ST, sternum.

Source: Fan Y, Kam K, So K, Lam YY, Lee APW. Imaging for Transcatheter Edge-to-Edge Repair for Tricuspid Regurgitation in Ebstein Anomaly. *Circulation: Cardiovascular Imaging*. 2021;14(11):e013327. doi:10.1161/CIRCIMAGING.121.013327.



Graphical abstract. Main findings of the automated LAA software and its validation study.

Source: Morais P, Fan Y, Queirós S, D'hooge J, Lee APW, Vilaça JL. Feasibility and accuracy of automated three-dimensional echocardiographic analysis of left atrial appendage for transcatheter closure. *Journal of the American Society of Echocardiography*. 2022;35(1):124-133. doi:10.1016/j.echo.2021.08.023.

